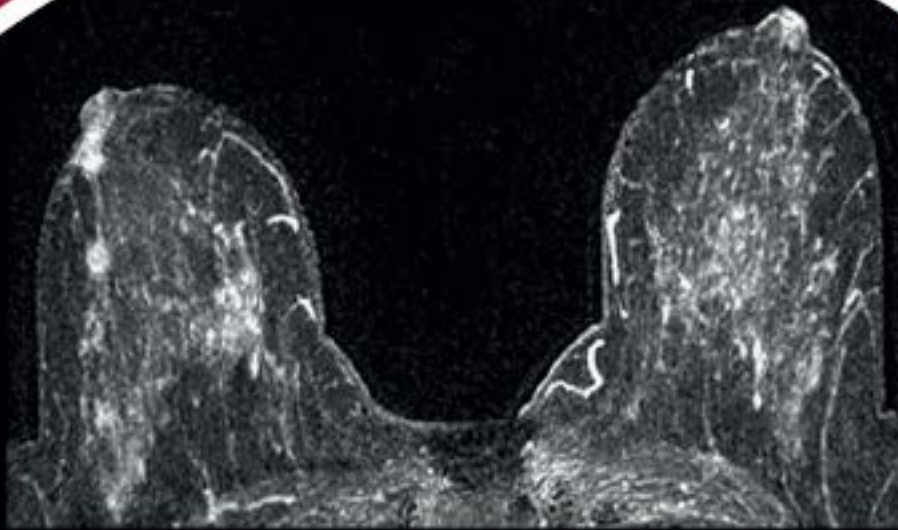


ESMRMB

European Society for Magnetic Resonance in Medicine and Biology



**REGISTER
NOW!**

www.esmrmb.org

School of MRI 2016

European Multidisciplinary

Advanced Breast & Female Pelvis MR Imaging

**October 20–22, 2016
Athens/GR**

Programme director:
Siegfried Trattnig, Vienna/AT

Course organiser:
Riccardo Manfredi, Verona/IT

Local organisers:
L. Mouloupoulos, Athens/GR
P. Prassopoulos, Alexandroupoli/GR

Advanced Breast & Female Pelvis MR Imaging

24

**October 20–22, 2016
Athens/GR**

**Course organiser:
Riccardo Manfredi
Verona/IT**



Local organisers:

L. Mouloupoulos, Athens/GR

P. Prassopoulos, Alexandroupoli/GR

Course venue:

Areteion Hospital

University of Athens, School of Medicine

76 Vass. Sophias Ave.

11528 Athens

Greece

Preliminary faculty:

B. Hamm, K. Kinkel, R. Kubik, R. Manfredi,

V. Martinez de Vega, S. Mehrabi, T. Metens,

M. Müller-Schimpfle, A. Rockall, L. Umutlu, D. Weishaupt

Course duration:

Thursday morning – Saturday noon

The aim of this course:

Technical advances have opened up new diagnostic applications in female MR imaging with MRI gaining an increasing role in this patient population also in a clinical routine setting.

This course will offer an overview of current MR imaging strategies for the diagnosis of breast and pelvic diseases including foetal imaging and pelvic floor MRI. Established as well as potential future indications will be reviewed compared to other imaging examinations. We will discuss hard- and software requirements of MR systems for optimal clinical use as well as the optimisation of imaging strategies and diagnostic advantages arising from the application of contrast agents.

The aim of the course is furthermore to convey in depth knowledge of morphological changes of the breast and pelvic female organs under pathological conditions.

We would like to welcome you to this course in Athens/GR, where European experts in the field of female MR imaging will be given the opportunity to share their knowledge with you in plenary lectures and reinforce the information in small group discussion.

Participation requirements:

Physicians who have good knowledge in MR techniques and some experience in applied MRI of the breast and female pelvis.

Become a
member and benefit
from reduced
registration fees

Learning Objectives

MR Imaging Techniques (Breast & Female Pelvis)

- Hard- and software requirements
- Basic pulse sequences for breast and pelvic MRI
- Advanced pulse sequences (including ultrafast sequences)
- Image post-processing
- Recent and future developments

Female Pelvis:

Protocol Optimisation, Benign Disease of the Uterus

- Optimised MR imaging strategy
- Normal MR appearance of the female pelvis according to age and menstrual cycle
- Muellerian duct abnormalities: Indication for MRI compared to HSG and US
- To diagnose and differentiate leiomyoma from adenomyosis
- Questions to be answered by MRI before and after leiomyoma embolization

MR Imaging of the Cervix and the Uterus:

Malignant Lesions

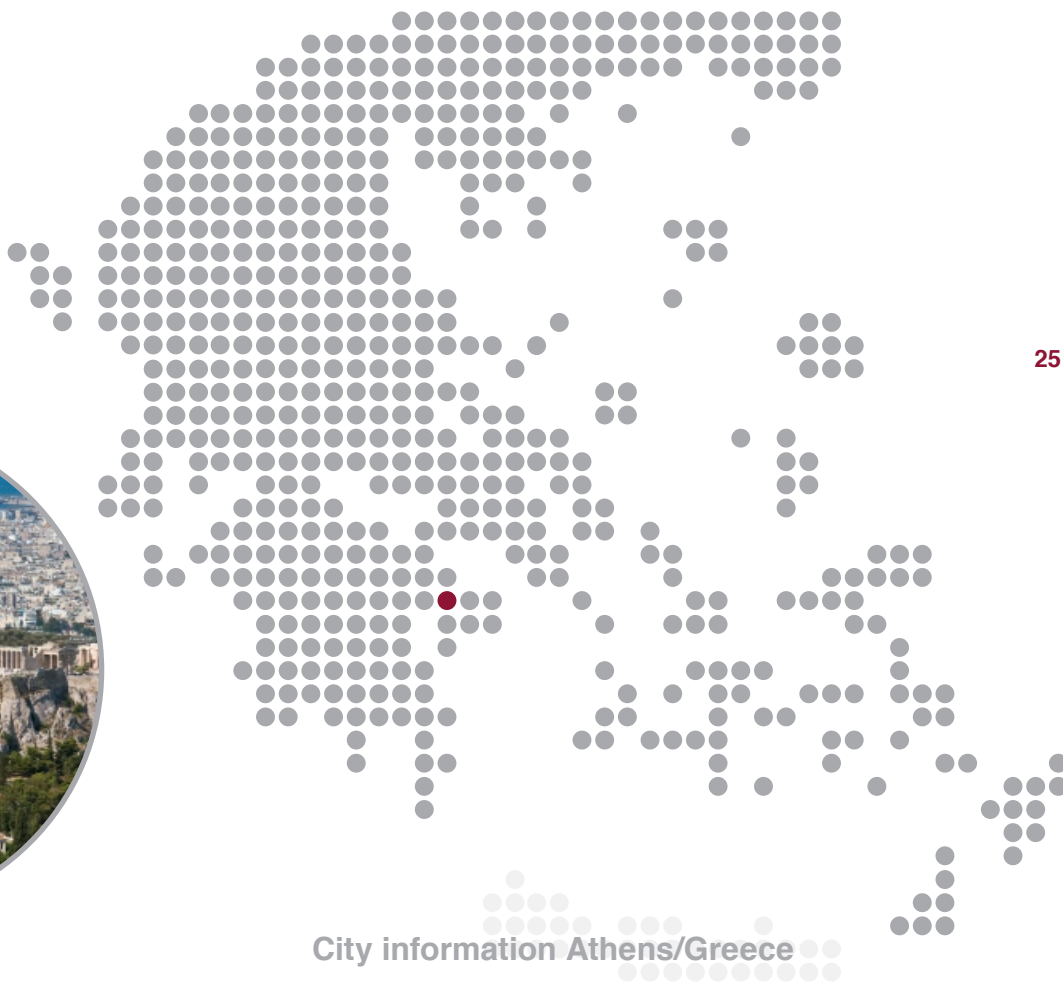- Optimised MR imaging strategy
- MR appearance of malignant lesions of the cervix
- MR appearance of malignant lesions of the uterus
- Staging of malignancies
- Follow-up of malignant tumours

MR Imaging of the Ovaries

- Optimised MR imaging strategy including DWI
- Appearance of the normal ovaries on T1-, and T2-weighted images and the enhancement patterns
- Indications for MRI compared to US and CT for imaging in patients with adnexal masses
- Benign and malignant lesions
- Staging and follow-up of ovarian carcinoma

MR Imaging of the Pelvic Floor

- Hard- and software requirements
- Application of open magnet systems
- Optimised MR imaging strategy
- Anatomy of the pelvic floor
- Indications for MRI in the incontinent patient
- Ano-rectal diseases



City information Athens/Greece

Population:	approx. 665.000 3.750.000 (metropolitan area)
Time zone:	CET+1/ EET
Currency:	EUR
Country dialling code:	+30
Closest Airports:	Athens International Airport (AIA) - Eleftherios Venizelos

Athens is noted to be the historical capital of Europe, with a long and detailed history, dating from the first settlements in the Neolithic age. For millennia Athens has been conquered by a multitude of occupiers erecting fascinating and impressive monuments. Since 1834, Athens has become the capital of the modern Greek state remaining a world centre of archaeological research. The Town's historic centre has been developed into a 3-kilometre pedestrian zone, the largest in Europe. It leads visitor to the major archaeological sites ranging from the temple of Olympian Zeus to the Odeion of Herodes Atticus. From there visitants climb up to the sacred rock of the Acropolis leading to the most important masterpieces of worldwide architecture. Also the famous Acropolis Museum is situated nearby.

Transportation:

Athens International Airport (AIA) "Eleftherios Venizelos" is located about 20 km (12 miles) east from Athens centre. EXPRESS* Bus routes run by the Public Bus company ETHEL (Public Bus Company) connect the airport with the city centre, Piraeus (port) and the greater area. All buses leave from the Arrivals Level on a non-stop basis seven days a week. The line X95 goes directly to the city centre and leaves every 15 minutes. Passengers get a one-way ticket for € 5,-. Connections from the AIA Rail Station are provided either by suburban rail for € 8,- or by the metro trains (line 3) for € 5,-. A taxi ride to the city centre inner ring costs approx. € 38,-, and takes travellers 45 minutes.

Hotel information: www.school-of-mri.org

MRI in the Obstetric Patient/Fetal MRI

- Safety considerations
- Contrast agents in the pregnant and nursing patient
- Optimised MR imaging strategy, including ultrafast sequences
- Indications for MRI in the obstetric population
- MRI of the healthy foetus and the utero-placental unit
- Morphological changes in foetal malformation and pathology

Technical Aspects of Breast MRI

- Hard- and software requirements
- Currently used 2D and 3D techniques
- Post-processing of the source images
- Importance of temporal and spatial resolution
- New sequences: Diffusion-weighted image (DWI) and spectroscopy of the breast

MR Imaging of the Breast

- Breast imaging protocol
- BIRADS-classification for breast MRI
- Indications of breast
- Pitfalls & limitations
- Interventional techniques in breast MRI
- Breast MRI following breast surgery
- Breast implants and implant failure

MRI of the Breast: Screening the high Risk Population

- Pros and Cons of breast cancer screening using MRI
- How to select women who benefit most?
- How and when to perform MRI?

MRI: Lymph node Staging

- Imaging strategy
- Plain MRI
- Contrast-enhanced MRI
- Lymphatic spread in uterine tumours